

PNEUMONIA FRAMED

Issue 1 | 2023



Dr. Rajendra Nanavare

Chest Physician

MBBS, Diploma in Tuberculosis Diseases (TDD)

Pulmonologist

Specialities in Chest and TB

Hon Chest Physician and Ex Medical superintendent of GTB hospital sewri Mumbai

Faculty for PG Dip in Chest & TB, PG Dip in Tropical medicine in college of physicians & surgeons, Parel

Editorial Manager of Indian journal of Tuberculosis.

A case of chronic smoking associated with Acute Bronchitis Complicated by Pneumonia

Case presentation

A 58-year-old retired truck driver presented with a four-day history of a harsh, productive cough accompanied by thick, yellow sputum with blood streaks. He developed a fever, shaking, chills, malaise, and right-sided chest pain exacerbated by inspiration.

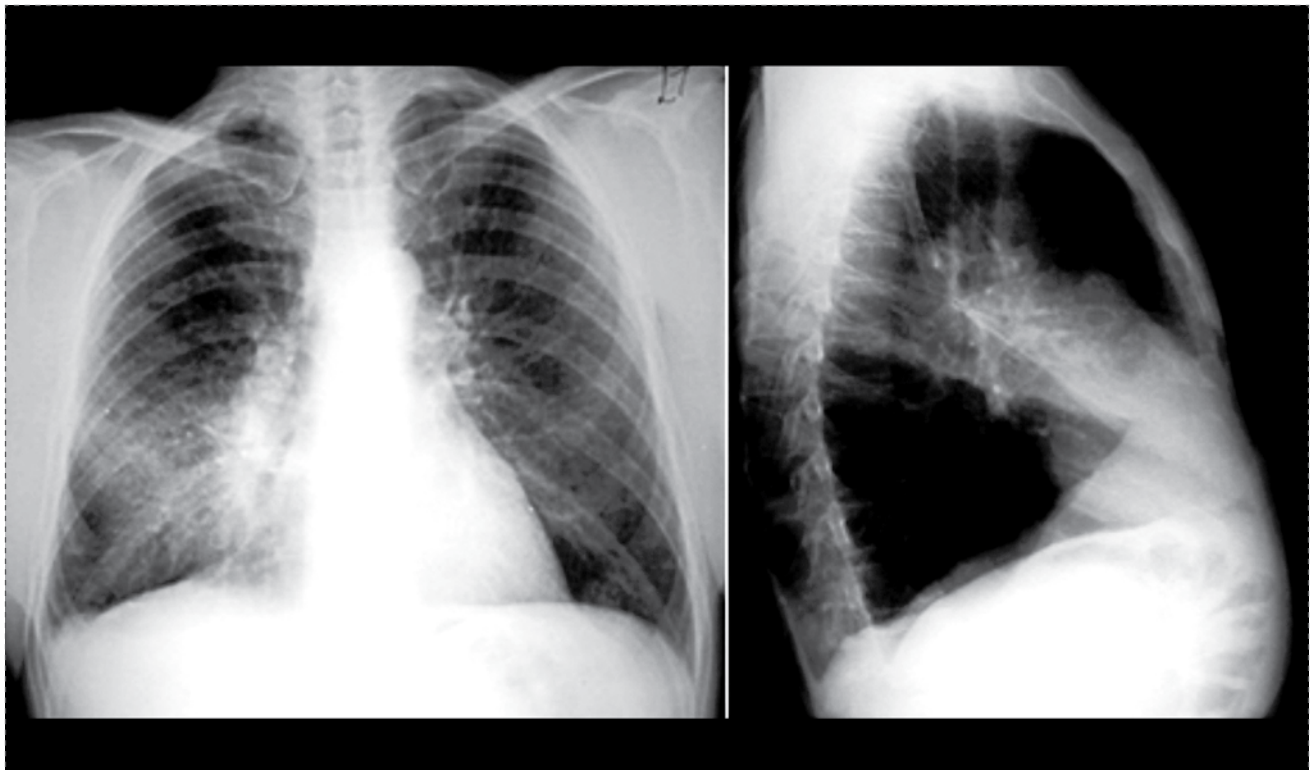


Figure 1. Acute pneumonia in the right middle lobe

History

The patient had a history of mild hypertension and bronchitis. He had been a chronic smoker for 10–15 years and has had mild, non-productive morning cough for the past few months. He has reported having lost 4 kgs of weight over past 1 year, but his appetite remained intact.

Physical examination

The patient appeared tired, haggard, and underweight, with a sallow complexion. Continuous coughing was evident, and right-sided chest pain worsened with inspiration. Lung examination revealed dullness in the right mid-anterior and right mid-lateral lung fields, with bilateral diminished vesicular breath sounds. Bronchial breath sounds, rhonchi, and late inspiratory crackles were heard in the affected lung area. Finger clubbing was present.

Laboratory investigation

Complete Blood Count (CBC):


- Hemoglobin (Hb) – 13.5 g/dL; Hematocrit (Hct) – 40%; Red Blood Cell Count (RBC) – 4.5 million/mm³; Platelet Count: 250,000/mm³; White Blood Cell Count (WBC) – 17,000/mm³ (elevated); Neutrophils – 70% (elevated); Bands – 15% (elevated); Lymphocytes – 15% (elevated); Random blood sugar – 125 mg/dL

Lipid Profile:

- Total Cholesterol – 250 mg/dL; LDL Cholesterol – 180 mg/dL; HDL Cholesterol – 40 mg/dL; Triglycerides – 200 mg/dL

X-ray

Chest X-ray (posteroanterior view and lateral) revealed an acute pneumonia in the right middle lobe.



Diagnosis

Based on the clinical presentation and chest X-ray, the patient was diagnosed with secondary bacterial pneumonia in the right middle lobe.

Microbiological reports

Sputum Culture

The sputum culture report showed the presence of bacterial infection, predominantly *Streptococcus pneumoniae*.

Blood Culture Sensitivity

The blood culture results demonstrated the presence of bacterial infection, predominately *Streptococcus Pneumoniae*. The culture showed sensitive to cefuroxime among other antibiotics such as Vancomycin and Ceftriaxone. This strain was found to be resistant to amoxicillin, macrolides, and fluoroquinolones.

Treatment

- The patient was initially prescribed amoxicillin/clavulanate (875/125mg orally twice daily) for 7 to 10 days, along with supportive measures. However, after two days, the patient's symptoms worsened, and they returned to the emergency department with increased shortness of breath and pleuritic chest pain.
- On reevaluation, the patient appeared acutely ill with respiratory distress, low oxygen saturation (88%), and a fever (39.1°C).
- Crackles and dullness were heard on lung examination, and arterial blood gas analysis revealed hypoxemia and respiratory alkalosis.
- After the blood culture was obtained, the patient was promptly admitted to the hospital and started on intravenous antibiotics intravenous piperacillin-Tazobactam 4.5 g

every 6 hours and supplemental oxygen therapy to maintain oxygen saturation above 92%.

Follow-up

- Over the next few days, the patient's respiratory status improved, and his fever subsided. Repeat chest X-ray showed resolution of the infiltrates.
- The patient was gradually weaned off supplemental oxygen and was discharged on a ten-day course of oral antibiotics (Cefuroxime 500 mg + Clavulanic acid 125 mg every q12 PO).
- Follow-up at two weeks revealed complete resolution of symptoms and no radiographic abnormalities.

Conclusion

In conclusion, this case report highlights a 58-year-old retired truck driver with a history of bronchitis and chronic smoking who presented with secondary bacterial pneumonia in the right middle lobe. Following initial treatment with amoxicillin/clavulanate, the patient's symptoms worsened, necessitating hospitalization and a change to intravenous piperacillin-tazobactam which resulted in clinical improvement and resolution of symptoms and radiographic abnormalities upon follow-up. Upon discharge, the patient continued treatment with a ten-day course of oral antibiotics (Cefuroxime 500 mg + Clavulanic acid 125 mg every q12 PO) to ensure completion of the therapeutic course.

Discussion

Pneumonia is a major global health concern, with India accounting for 23% of cases. The case fatality rates in India range from 14% to 30%, and *Streptococcus pneumoniae* is a primary bacterial

cause. Pneumonia is characterized by sudden symptoms like dyspnea, cough, and fever, along with focal chest signs. A new pulmonary infiltrate on a chest X-ray confirms the diagnosis.¹ Tobacco use, even in passive smokers, increases susceptibility to bacterial lung infections, including *Streptococcus pneumoniae* and *Legionella pneumophila* in specific cases. Quitting smoking significantly reduces the risk over time and is recommended, along with pneumococcal vaccination, as preventive measures regardless of underlying health conditions.² In pneumonia, the cause is often unknown, so empirical treatment targets *Streptococcus pneumoniae* and atypical pathogens like *Mycoplasma pneumoniae* and *Legionella pneumophila*. The aim is broad-spectrum coverage based on local epidemiology, illness severity, and drug resistance risk factors.³ *Streptococcus pneumoniae* infection is a significant cause of illness and death. The recommendation to use expanded-spectrum β -lactam drugs for pneumonia patients stems from the increasing prevalence of penicillin-resistant pneumococci. A retrospective study on adult patients with pneumococcal pneumonia and bacteremia, caused by *S. pneumoniae* showing intermediate penicillin resistance, found that cefuroxime can be an effective empirical treatment option. In regions where fully resistant pneumococci

are uncommon, using a second-generation cephalosporin for empiric treatment of pneumonia may be suitable.⁴

Cephalosporins, particularly when combined with clavulanic acid, are considered superior to cephalosporin monotherapy in treating resistant infections. This combination has shown effectiveness in various community-acquired infections, including respiratory tract infections. With the increasing prevalence of extended-spectrum beta-lactamase (ESBL)-producing bacteria and the need for oral outpatient treatment options, the combination of a cephalosporin and clavulanate provides the advantage of oral administration and is an excellent choice for treating uncomplicated community-acquired infections caused by non-ampC ESBL-producing gram-negative bacteria.⁵

References

1. Eshwara VK, Mukhopadhyay C, Rello J. Community-acquired bacterial pneumonia in adults: An update. *Indian J Med Res.* 2020;151(4):287–302.
2. Almirall J, Blanquer J, Bello S. Community-acquired pneumonia among smokers. *Arch Bronconeumol.* 2014;50(6):250–4.
3. UpToDate. Overview of community-acquired pneumonia in adults. [Internet] 2023. Accessed: July 4, 2023. Available from: <https://www.uptodate.com/contents/overview-of-community-acquired-pneumonia-in-adults/print>.
4. Wiener-Well Y, Raveh D, Schlesinger Y, et al. Cefuroxime for empiric treatment of community-acquired pneumococcal pneumonia: Is there a generation gap? *Chemotherapy.* 2009;55(2):97–104.
5. Rawat D, Hasan AS, Capoor MR, et al. In vitro evaluation of a new cefixime-clavulanic acid combination for gram-negative bacteria. *Southeast Asian J Trop Med Public Health.* 2009;40(1):131–9.